Advancement of Endovascular Therapy: The Future of BTK / CLI Treatment

D. Scheinert, MD
Department of Angiology
Park Hospital & Heart Center, Leipzig, Germany

Presenter Disclosure Information

Name: Dierk Scheinert MD

Within the last 12 months, the presenter or their spouse/partner have had a financial interest/arrangement or affiliation with the organizations listed below.

Company	*Relationship*
Abbott	*Advisory Board*
Boston Scientific	*Advisory Board*
Cordis	*Advisory Board*
Square one	*Advisory Board*
Novostent	*Advisory Board*
Angioslide	*Advisory Board*
Gardia Medical	*Advisory Board*
Revascular Therapeutics	*Advisory Board*
Atheromed	*Consultant*
Angioscore	*Consultant*
Cook Medical	*Consultant*
Invatec	*Consultant*
Ev3	*Consultant*
Pathway Medical	*Consultant*
IDEV Techn.	*Stockholder*
CSI	*Stockholder*

CLI left leg
PTA of pTA

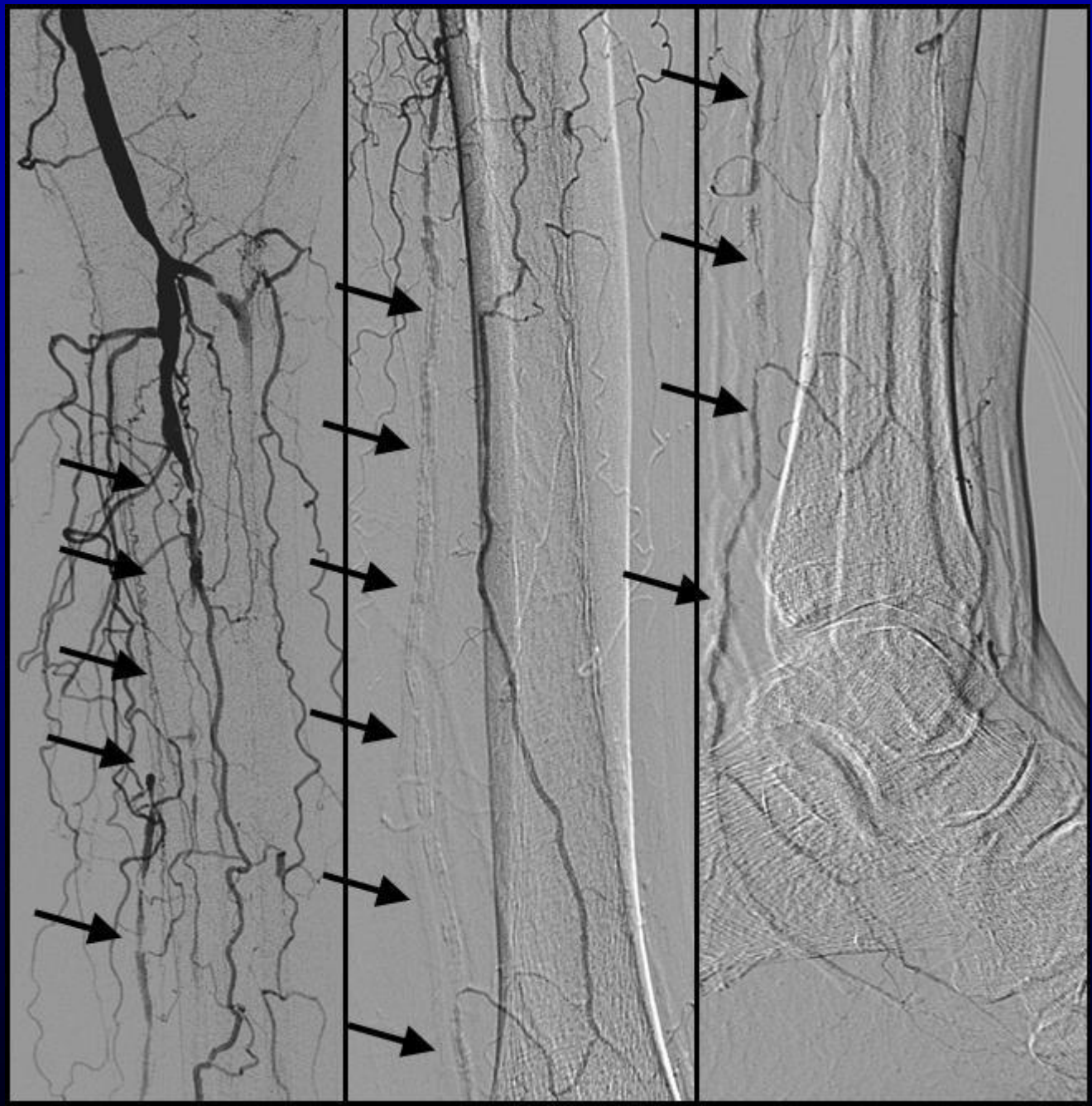

Guidewires for BTK-CTOs

- „Standard-guidewires“:
  - Hydrophilic tipped guidewires
    - ✓ 0.014“ PT2, PT Graphics (Boston Scientific)
    - ✓ 0.014“ Shinobi, 300cm (Cordis)
    - ✓ 0.018“ V18-Control (Boston Scientific)
    - ✓ 0.035“ Terumo (Terumo)
- Coronary 0.014“ CTO-guidewire
  - Miracle guidewire (Asahi, ABBOTT)
  - Confienza guidewire (Asahi, ABBOTT)

Most important recent development for infrapopliteal endovascular Treatment

- Long, low-profile balloons

- Tracking over 0.018“ guidewire
  - Pacific (Invatec), Savvy (Cordis)
  - Fox SV (Abbott), Sterling (BS)
  - Passeo 18 (Biotronik)

- Tracking over 0.014“ guidewire
  - Amphirion Deep, OTW + RX (Invatec)
  - Sleek RX (Cordis)

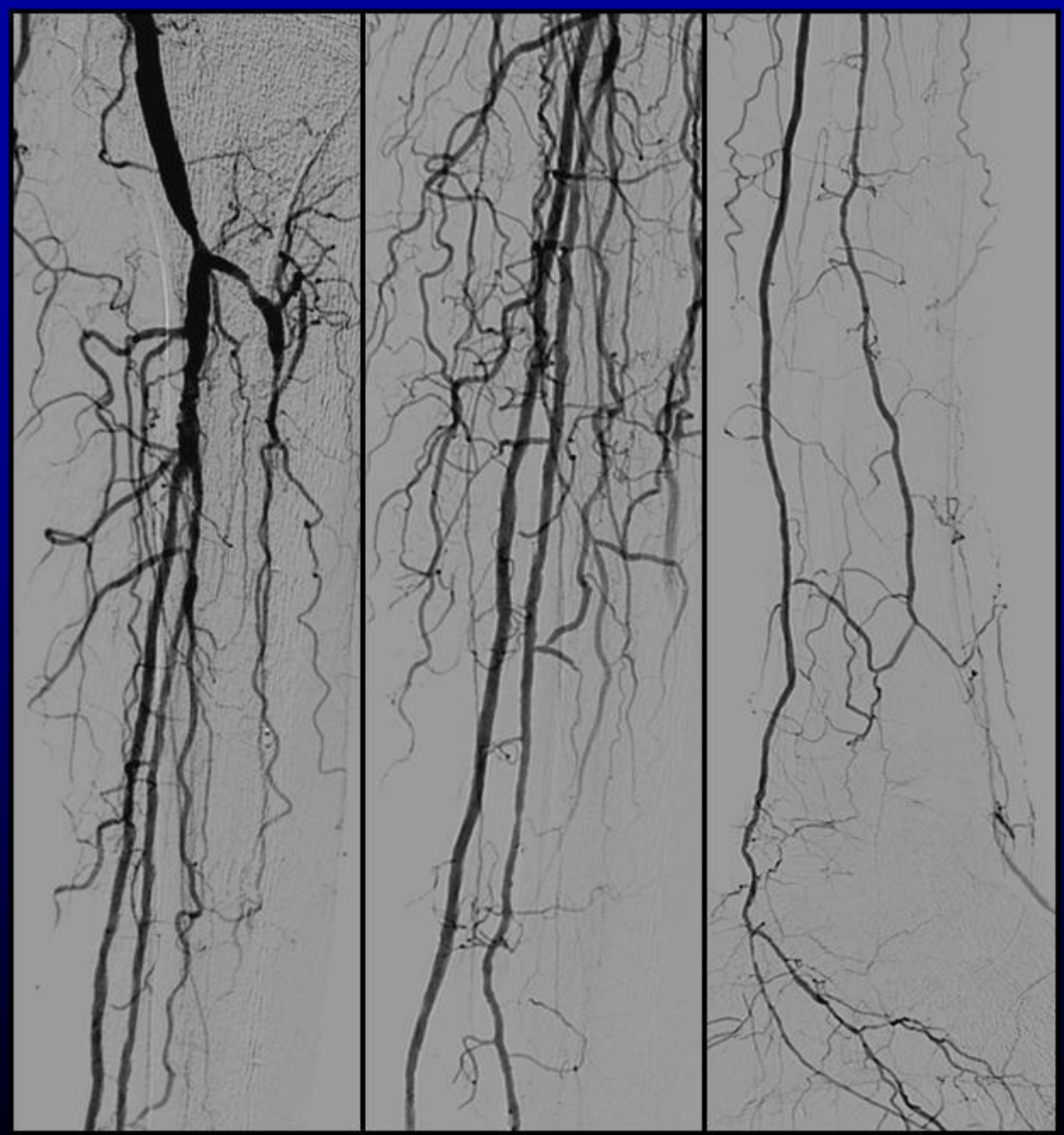

Angioplasty of Diffuse Infrapop. Lesions in Diabetes-Patients

Main problems:

- Crossing failures in CTO`s
- High restenosis-rate

How can we improve our results ?

Material for Transpedal Recanalization

- 21 Gauge puncture-needle
- 0.014“ or 0.018“ hydrophilic coated guidewires
- Low-profile balloons 2.0/120mm
- 0.014“ coronary CTO-guidewires

Sheathless Approach for Transpedal Recanalization

- For minimizing the trauma to the pedal artery

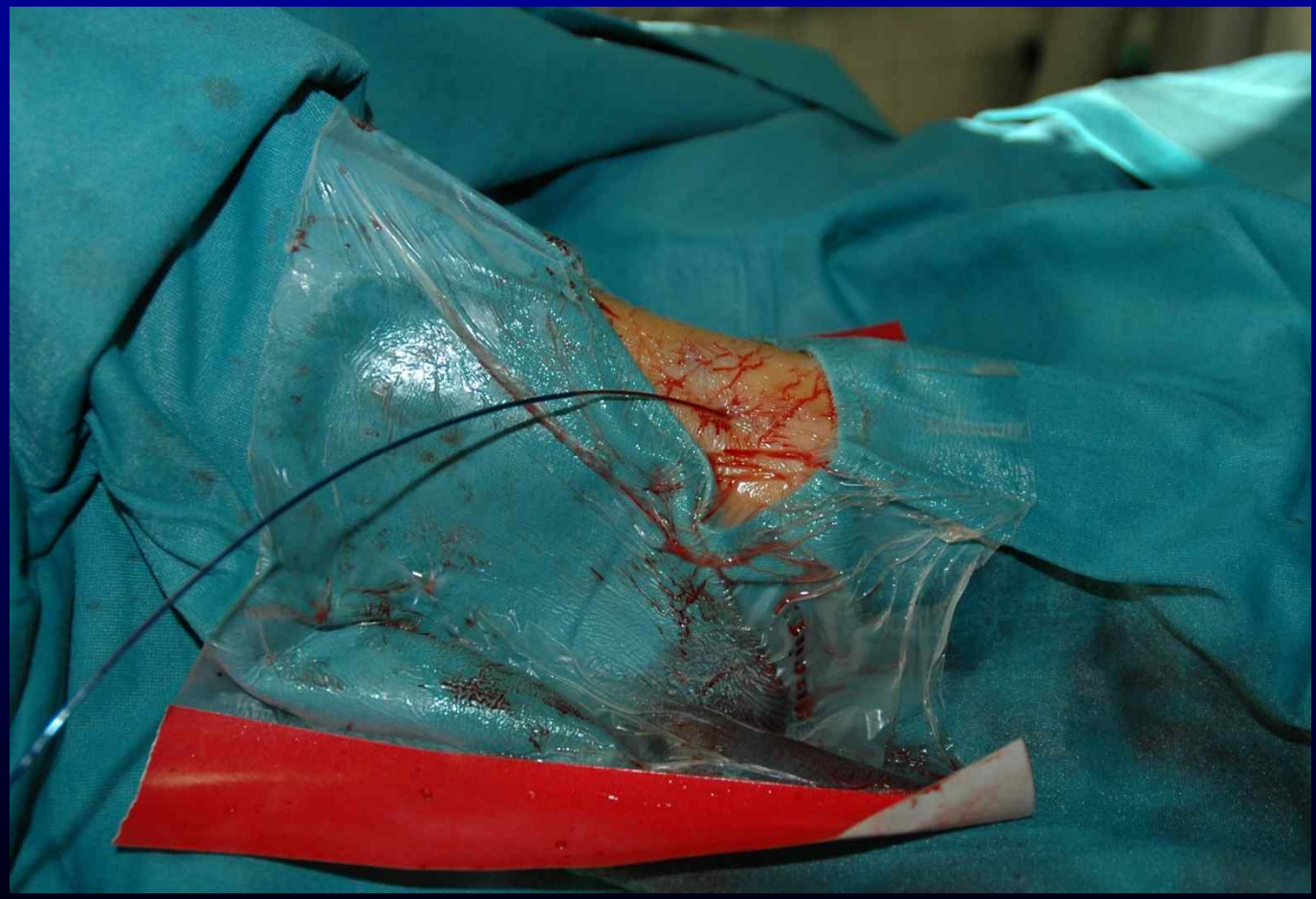

Puncture of the anterior, posterior tibial or peroneal artery

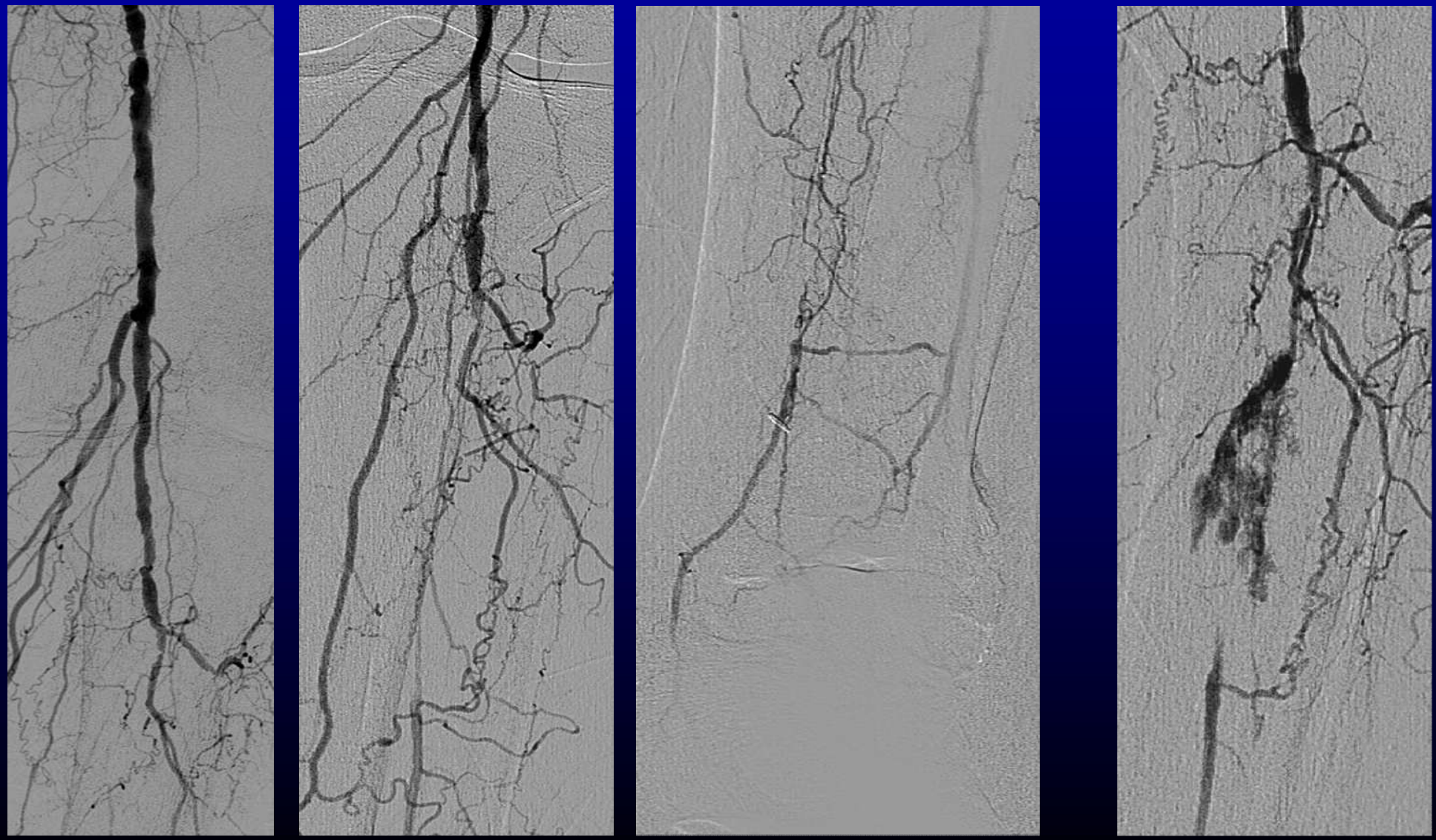

Difficult Passage of the guidewire to the PTA

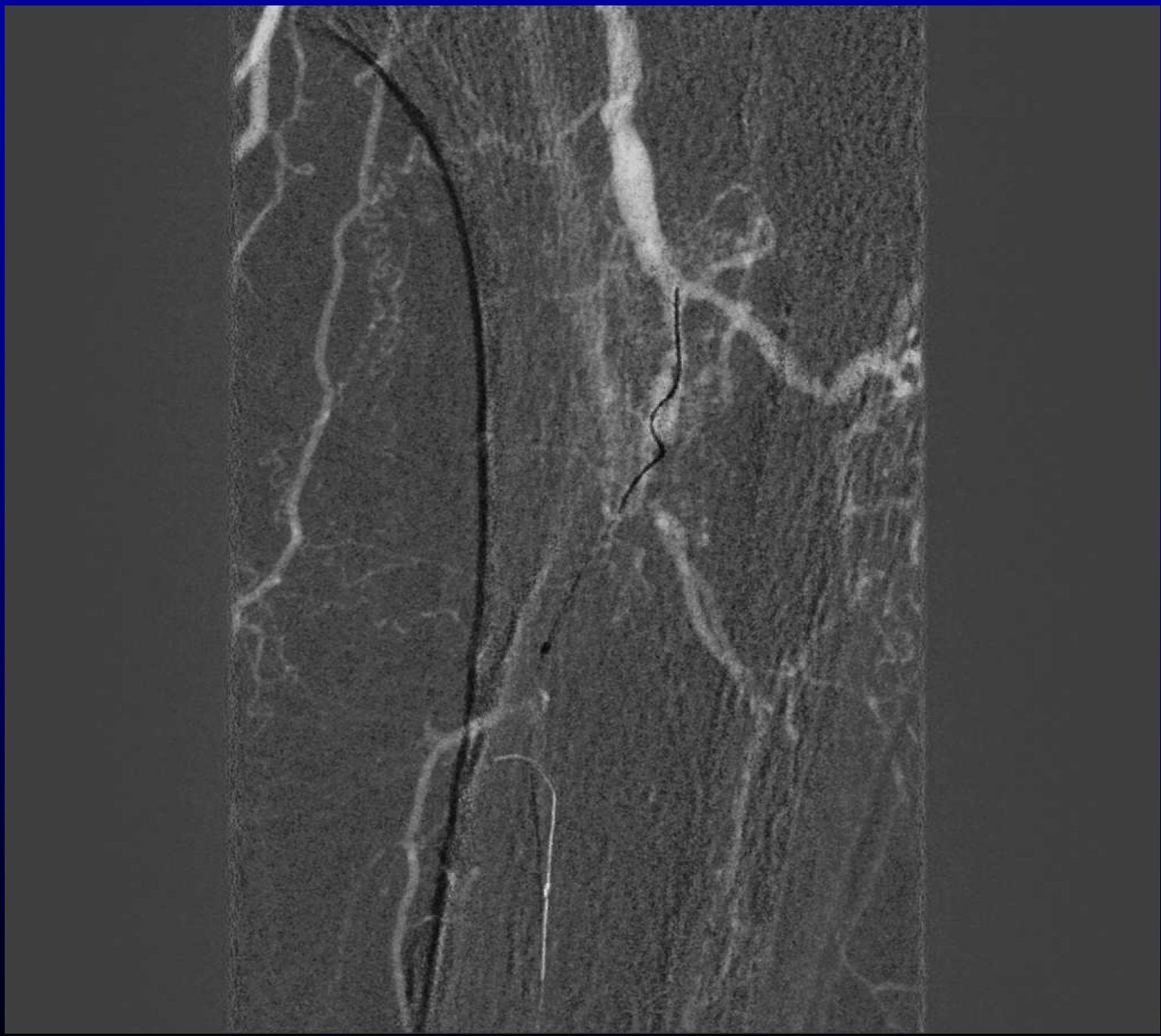

“Snaring of the Retrograde Guide-Wire”

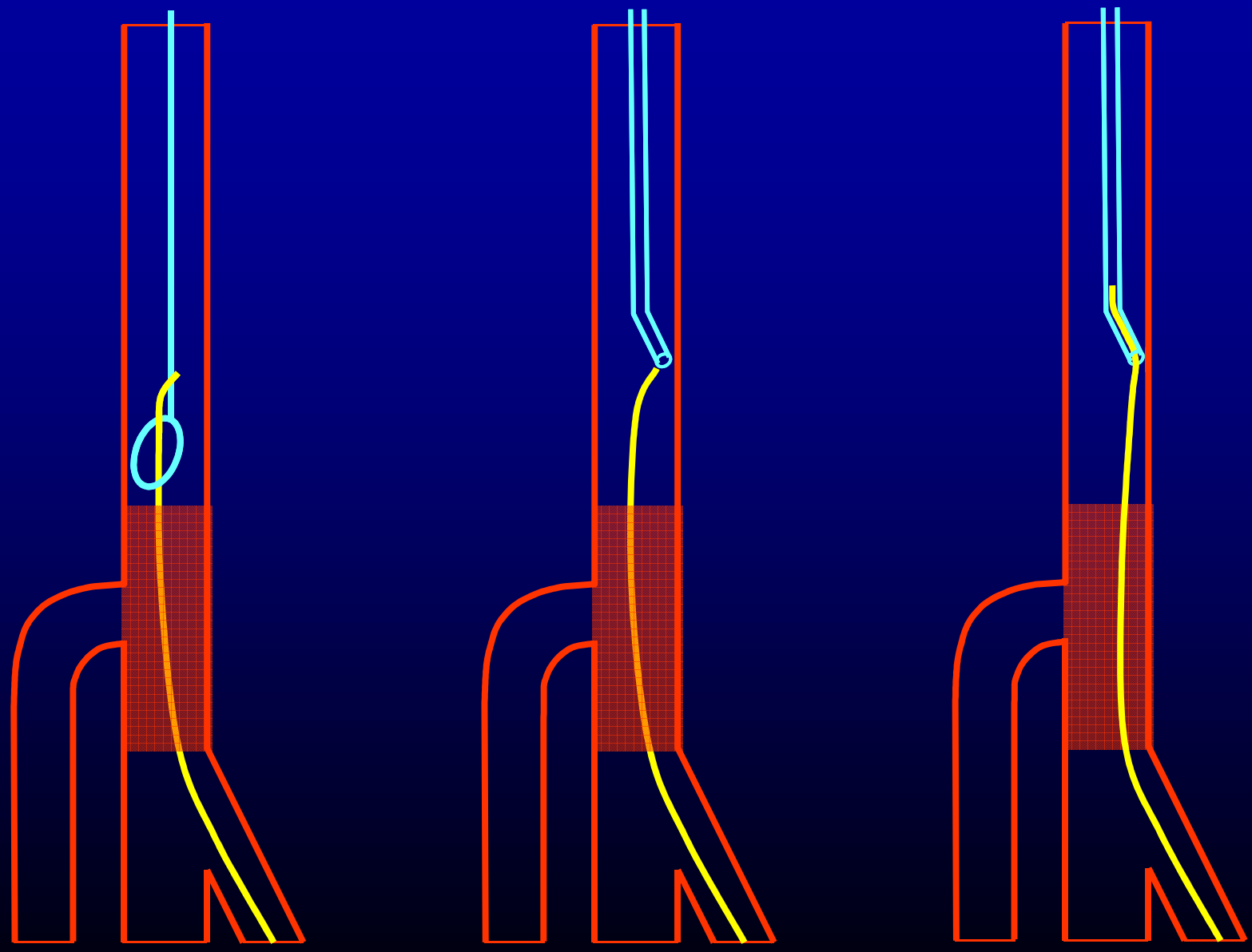

Snaring of the retrograde Guidewire

Antegrade
4Fr angled
Glidecath

Final Result after additional Stenting

The Double Balloon-Technique

antegrade – retrograde Intervention

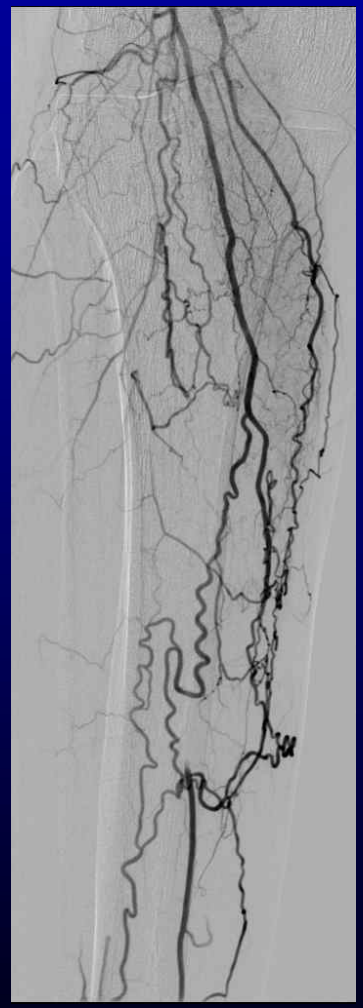

Unsuccessful antegrade PTA of the Apop-occlusion

Retrograde puncture of the PTA

The Double-Balloon Technique

“Rendezvous-Technique”

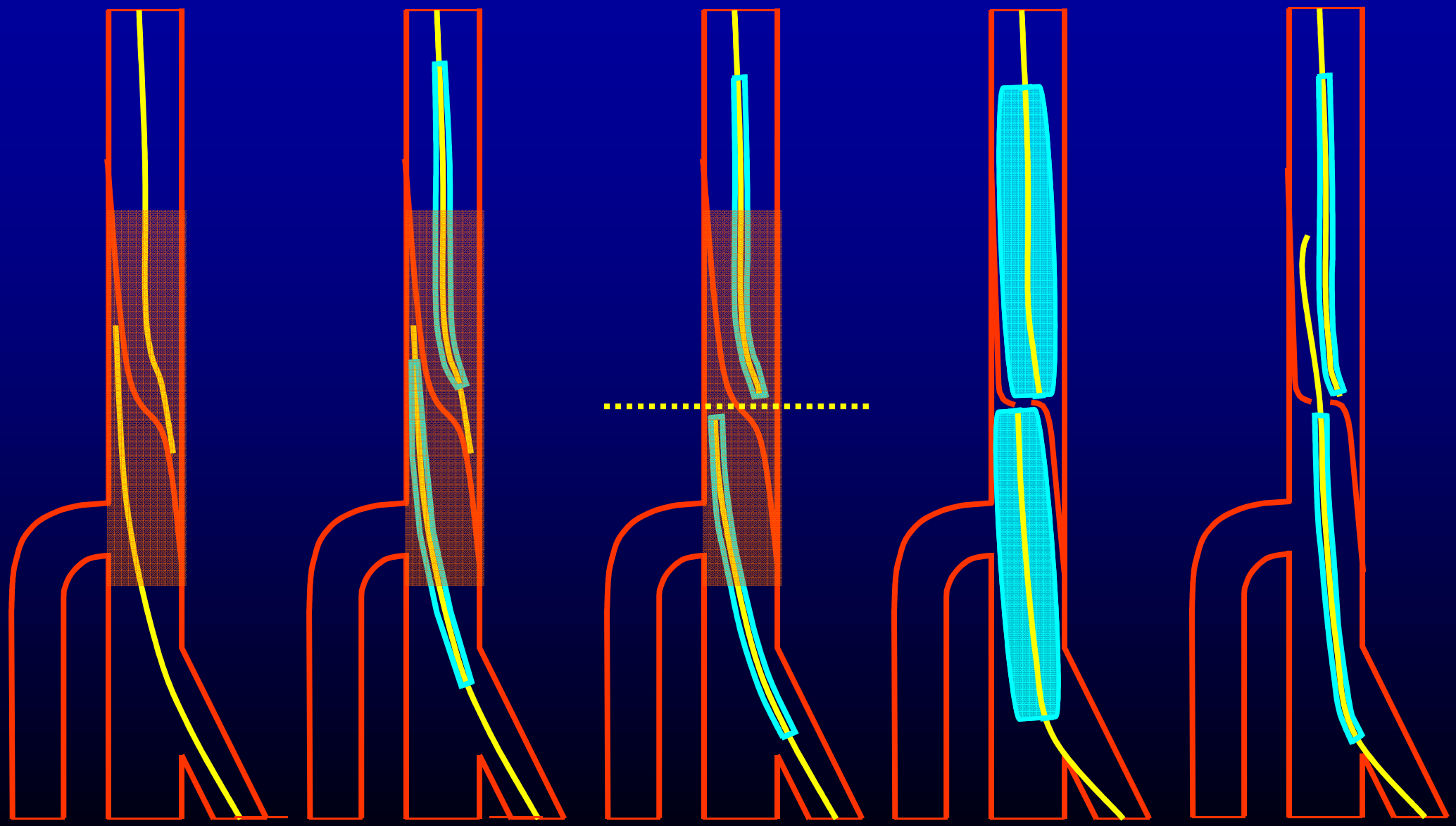

The Double-Balloon Technique

The Double-Balloon Technique

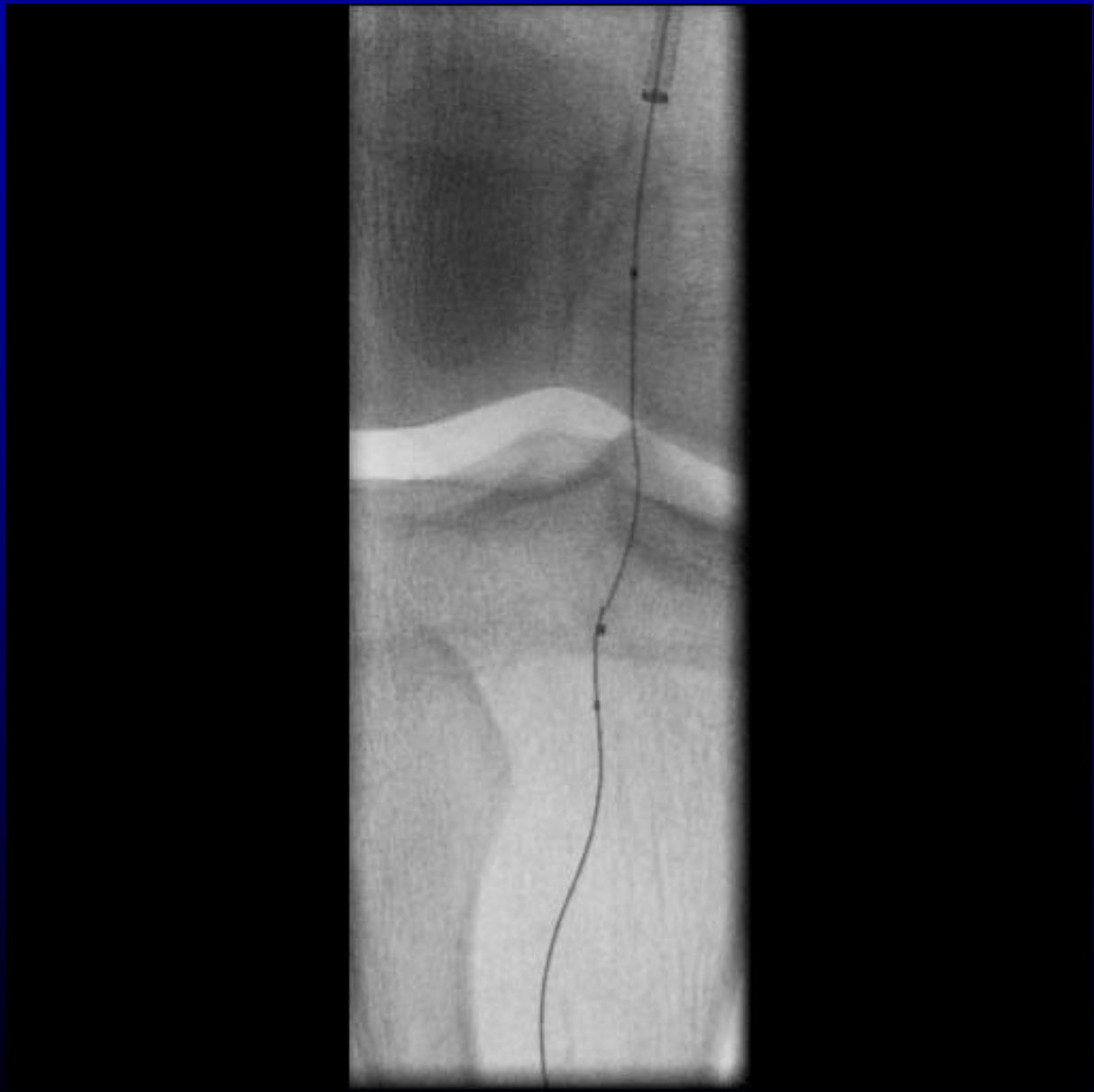

The Double-Balloon Technique

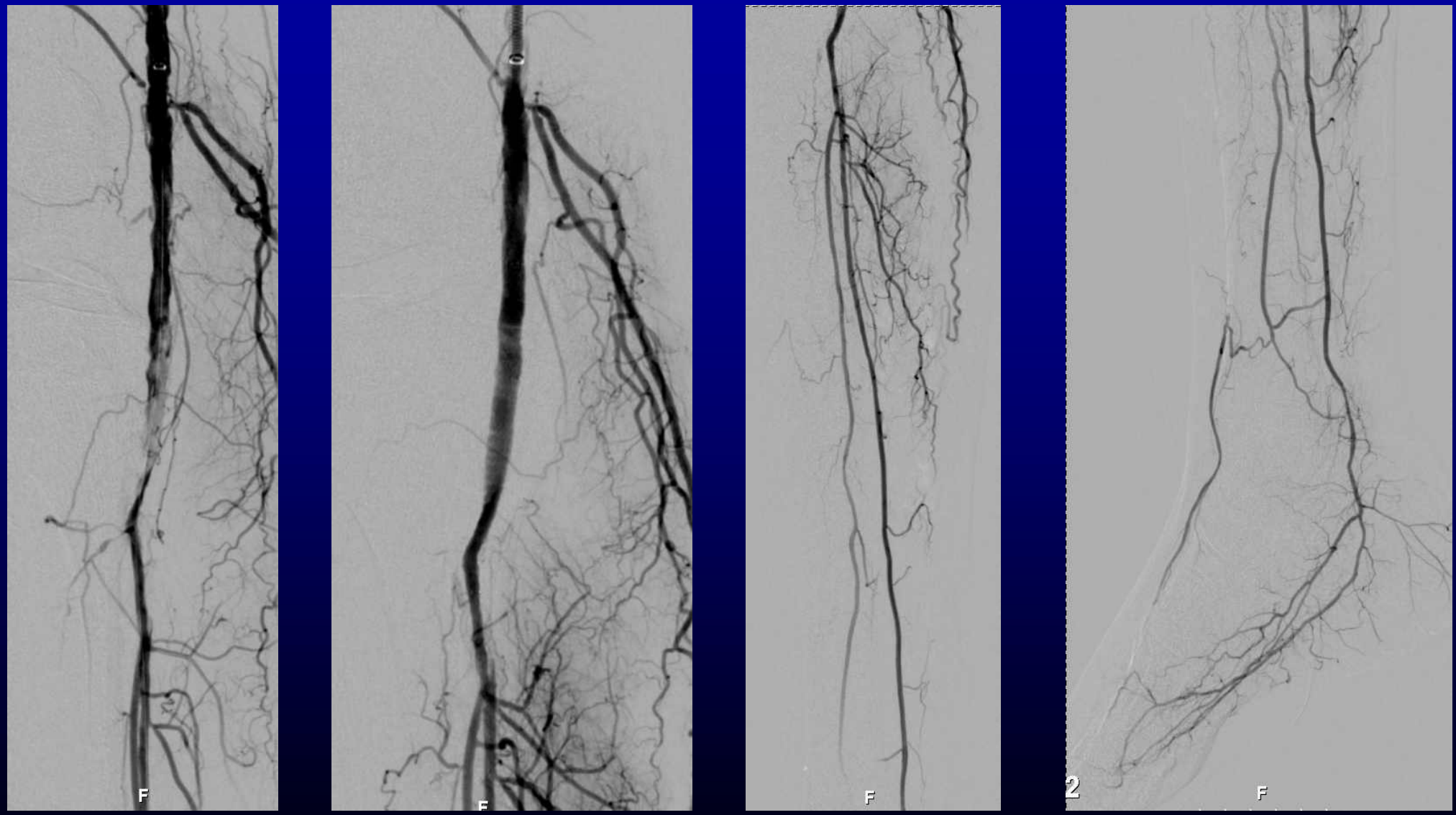

Transpedal Approach for infrapopliteal Angioplasty

- Success-rate in long BTK-occlusions **~ 80%**
- **51 patients** with popliteal and infrapopliteal occlusions and failed antegrade intervention
- Retrograde access in all patients possible
- Interventional success in 44 / 51 **(86.3 %)**

Montero-Baker, Schmidt et al., JEVT Oct. 2008

How to improve the long-term results?

- Drug-eluting stents

- Drug-eluting balloons

Baseline Clinical Data

	Cypher	Control	p
n	30	30	
Mean age	71,4	73,0	NS
Male gender	17 (56,7%)	19 (63,3%)	NS
Diabetes mellitus	25 (83,3%)	23 (76,6%)	NS
Arterial Hypertension	29 (96,6%)	30 (100%)	NS
HLP	19 (63,3%)	20 (66,6%)	NS
Smoker	9 (30,0%)	11 (36,6%)	NS

Angiographic Follow-up (6-12 Months)

	Cypher n=24	BMS n=23	p
Stent occlusion	0	4 (17,4%)	0,032
Restenosis > 50%	0	9 (39,1%)	0,0007
Grade of restenosis (mean)	1,8 ± 4,8 %	53 ± 40,9 %	< 0,0001

Scheinert et al. Eurointervention2006

SES vs. BMS for Bailout after Suboptimal Angioplasty for CLI

Degree of Restenosis	Cypher n=29		Control n=29
arteries	41		40
lesions	66		65
Restenosis in stent	4.0%	P<0.001	55.3%
Restenosis in segm	32.0%	P<0.001	66.0%
TLR	4.0%	P=0.02	17.0%

Siablis D et al. J Endovasc Ther 2006

Cypher – BTK Registry
- Angiographic Stent Patency -

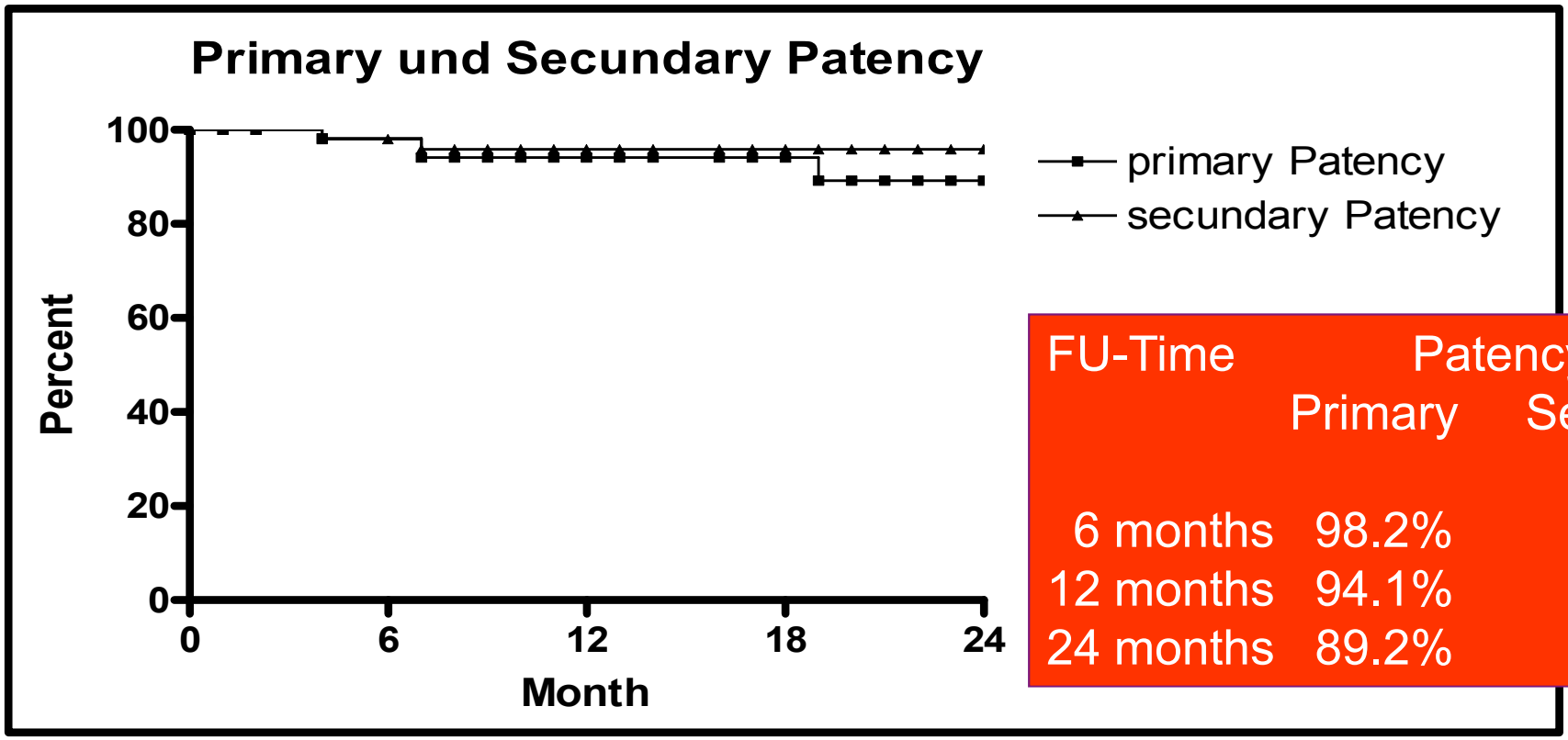

FU-Time	Patency	
	Primary	Secondary
6 months	98.2%	98.2%
12 months	94.1%	95.9%
24 months	89.2%	95.9%

Log Rank = 0,4551

Focal BTK Lesions: DES

Cypher Stent 3.5/33: 6 months FU

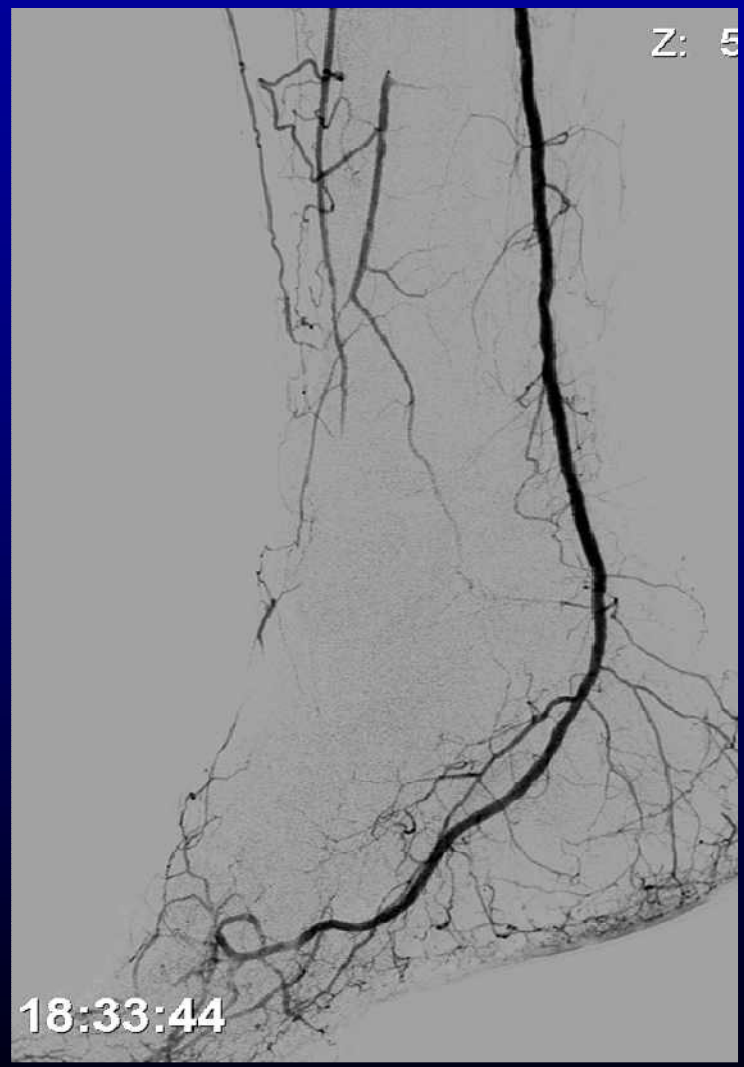

Long Diffuse BTK Lesions: DEB ?

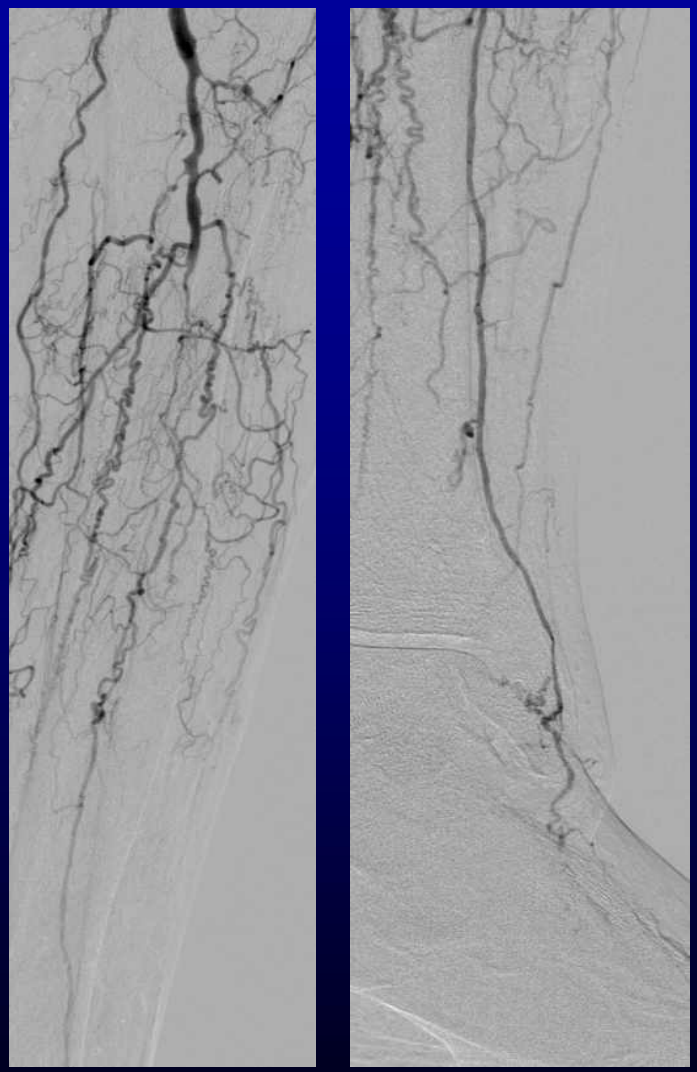

Peronal occlusion left

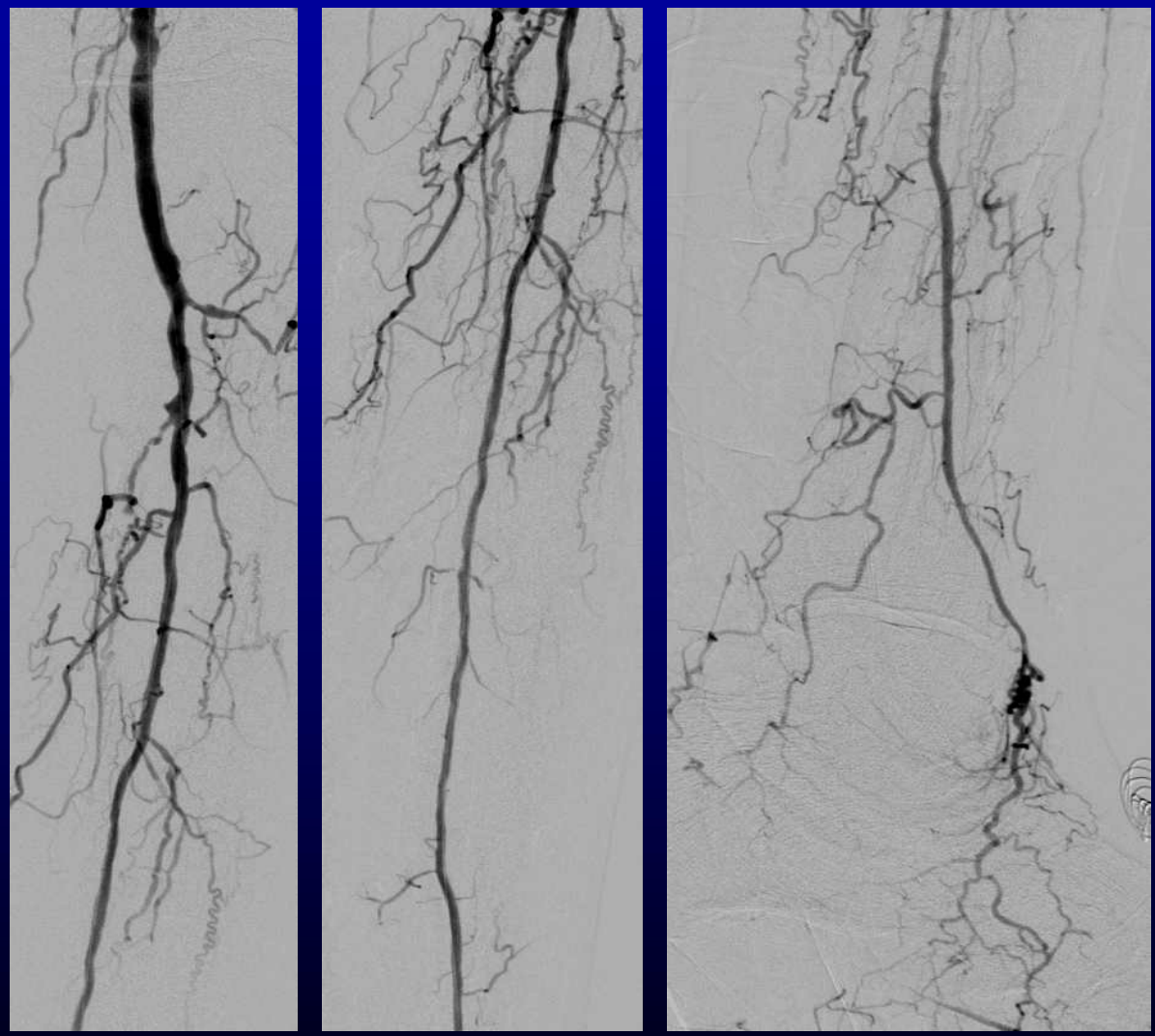

Inpact – Amphirion DEB (Invatec)

Leipzig Experience with DEB BTK

- Prospective registry of patients with BTK-lesions
- In.Pact Amphirion Deep Paclitaxel-eluting balloon
- (Invatec)
- Planned FU:
  - Angiography after 3 months
  - Clinical FU 3, 6 and 12 months

Preliminary Data
In.Pact Amphirion Deep BTK

- 116 patients treated with In.Pact Deep (Invatec)
- 64 patients within the 3-months window
- 2 patients died
  - 1 cardiac death
  - 1 due to major amputation
- 15 pts. did not come to the 3-mo FU

Preliminary Data
In.Pact Amphirion Deep BTK

- De-novo 28 (58 %)
- Restenosis 15 (31 %)
- In-stent restenosis 5 (11 %)

- Mean lesion-length 170 ± 76 mm

- Stenosis 20 (42 %)
- Occlusion 28 (58 %)

Preliminary Data
In.Pact Amphirion Deep BTK

Rutherford categories before and at 3 mo FU

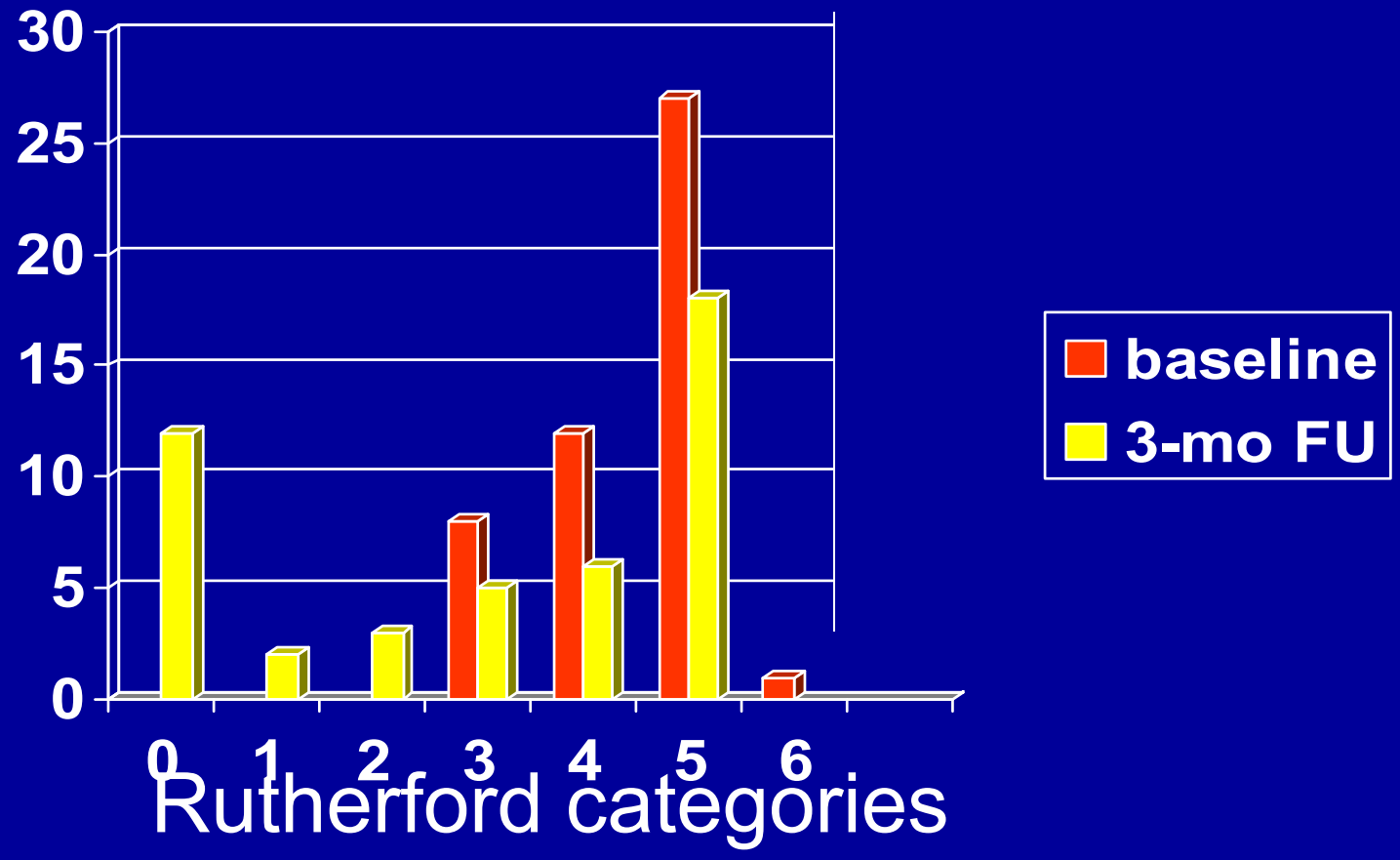

-Leipzig Experience with DEB BTK

-Leipzig Experience with DEB BTK

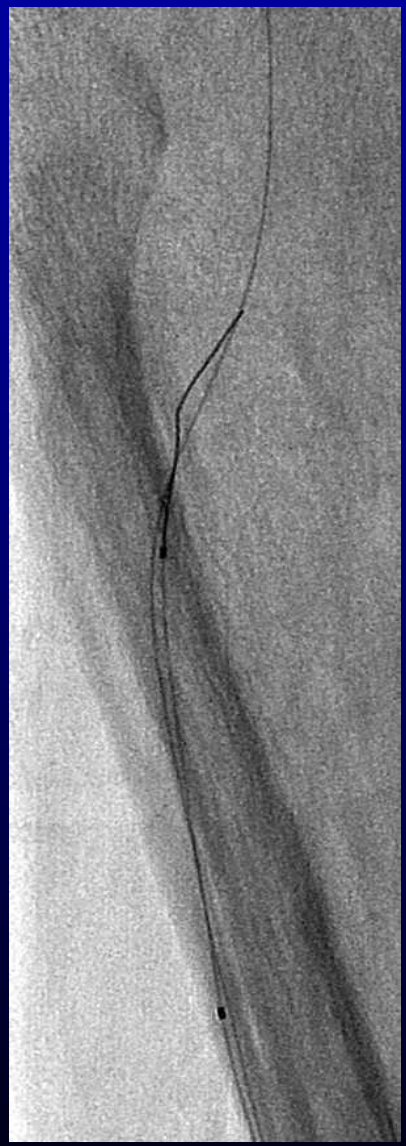

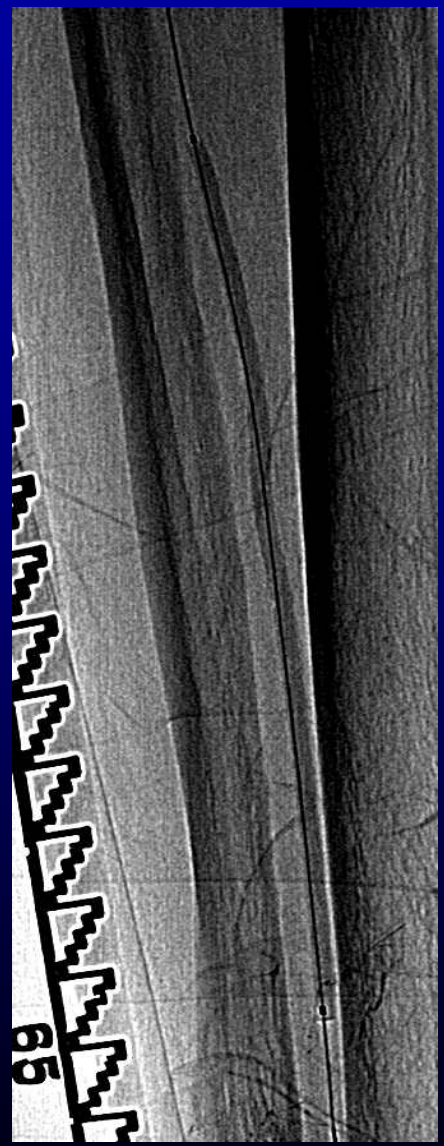



-Result after In.Pact Deep

-3-Months Follow-Up

-Leipzig Experience with DEB BTK

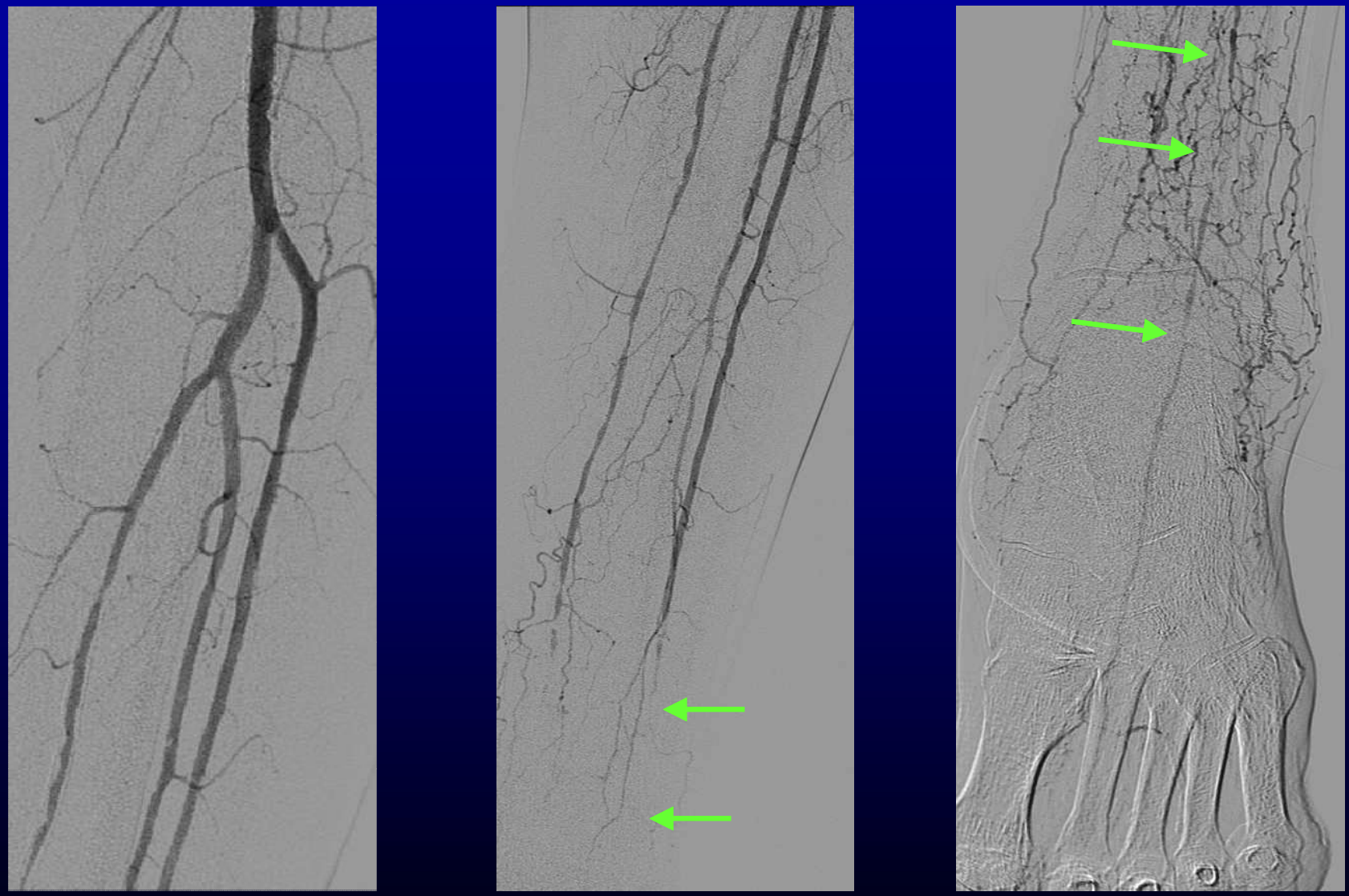

Distal ATA-Stenosis

-Leipzig Experience with DEB BTK

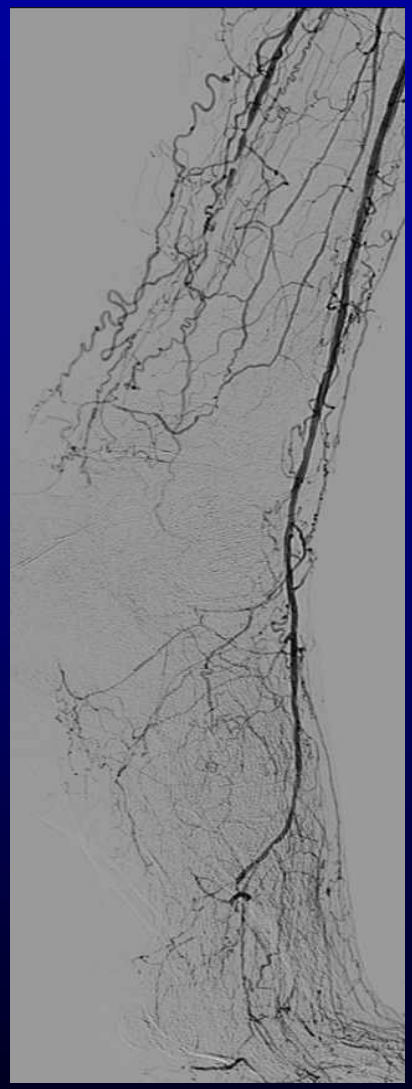

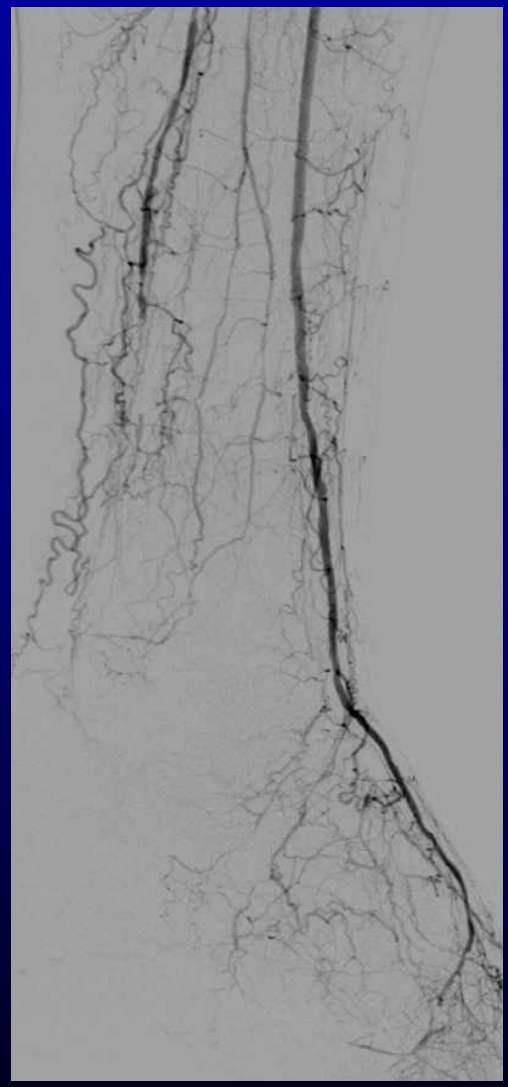

After 2.5/120mm In.PACT Deep

3 months – follow-up

Preliminary Data
In.Pact Amphirion Deep BTK

- No restenosis	33 / 48 (69 %)
- Restenosis > 50 %	15 / 48 (31 %)
- Focal restenosis	8 / 15 (53 %)
- Whole treated segment	7 / 15 (47 %)

-Leipzig Experience with DEB BTK

	POB BTK	DEB BTK
Restenosis > 50 % After 3 months	69 %	31 %
Restenosis of the whole treated segment	56 %	15 %

Conclusion

- BTK-angioplasty is a tremendously developing field

- Combination of latest interventional technologies and the use of alternative interventional approaches (transpedal /transcollateral) results in a very acceptable acute success-rate.

- DES and DEB have the potential to further improve the results of interventional recanalization